LETTERS TO THE EDITOR

ANZJSurg.com

Selected letters will be published on ANZJSurg.com before they appear in the print journal

Dear Editor,

There is still the best of reasons for all of us to be grateful to Sir Kenelm Digby

Professor Mellick is to be complimented for his biographical sketch of Sir Kenelm Digby, the exceptionally talented 17th-century polymath who dabbled in medicine among many other things.[1] Digby lived in a tumultuous time when science as we now know had begun to emerge.

Much has been written about Digby and his extraordinary accomplishments. He was the subject of the Wilkinson Lecture at Worcester College, Oxford, in 2005. This was given by Lesley Le Claire, the scholarly former college librarian. Le Claire had access to the treasure trove of Digbiana in the college. The college holds nearly all of Digby's publications and many of them are first editions. The erudite lecture added some further insights into the life of this man for most (?all) seasons.

As a Catholic, Digby could not become either a full member of Oxford or of one of its colleges. Neither could he take a degree. However, in the early 17th century, provisions were made for Catholics to attend Gloucester Hall, Oxford, an organization with a chequered Benedictine-linked history and which later evolved into Worcester College. It was at Gloucester Hall that Digby came under the influence of the mathematician Thomas Allen who dubbed him '*the Mirandola of his age*',[2] an extraordinary anointment for the intellectually precocious 15-year-old.

Le Claire records that Digby was far from alone in his contention that the Powder of Sympathy was efficacious in promoting wound healing. He also stated, '*The fact that healing often did occur has a simple explanation. Digby insisted that the wound itself should be kept absolutely clean with no application of the extremely dubious ointments in current use. Unwittingly, he was aiming at asepsis – a lesson that our modern hospitals are having to re-learn*'.[2]

Le Claire makes a notable point in his observation that '*Perhaps his greatest legacy is to the world of literature – not only at the material level of his generosity to libraries and his patronage of contemporary writers – but also in a more subtle sense: his vivid personality caught the imagination of writers long after his death*'.[2]

It is well recorded that Digby more than dabbled in epicurean delights of the table and this may well have contributed to his eventually fatal trouble with 'the stone'. Nevertheless, the English-speaking world is, perhaps unknowingly, forever indebted to this *bon vivant* for it was he who was '*the first to recommend bacon and eggs for breakfast*'[2] – still the unbeatable, gustatory quinella with which to start the day.

References

1. Mellick SA. Sir Kenelm Digby (1603–1665): diplomat, entrepreneur, privateer, duellist, scientist and philosopher. *ANZ J. Surg.* 2011; **81:** 911–4.
2. Le Claire L. Kenelm Digby – '*The Mirandola of his age*'. *The Wilkinson Lecture 2005.* Worcester College Record 2005: 51–69.

Thomas K. F. Taylor, FRACS, DPhil (Oxon)
Emeritus Professor of Orthopaedics and Traumatic Surgery, The University of Sydney, North Shore Private Hospital, Sydney, New South Wales, Australia

doi: 10.1111/j.1445-2197.2012.06020.x

Dear Editor,

Endoscopic ultrasound-guided fine needle aspirate: a useful method in the diagnosis of pancreatic tuberculosis

The incidence of tuberculosis (TB) in Australia has historically been low but has risen in recent years to five to six cases per 100 000 population,[1] as compared with the Western Pacific and South East Asian regions, which have incidence rates of 108 and 181 per 100 000 population, respectively.[2] Pancreatic TB is a rare diagnosis that can mimic pancreatic malignancy and its diagnosis represents a clinical challenge in view of its non-specific clinical presentation.

We present the case of a 23-year-old woman of Indian origin who had been living in Australia the past 6 years. She presented with a 5-month history of fever, cough and weight loss. She had past Bacillus of Calmette Guérin scar and her chest radiograph was unremarkable. A QuantiFeron Gold tested positive. Abdominal ultrasound and computed tomography (CT) scan revealed a pancreatic mass. Endoscopic ultrasound (EUS) delineated a 2.76×2.05-cm hypoechoic mass in the head of the pancreas with two small subcentimeter lymph nodes present (Fig. 1); EUS-guided fine needle aspirate (FNA) of the lesion was performed. Cytology showed no malignant cells and no acid-fast bacilli. Antituberculous empiric treatment was started with isoniazid, rifampicin, ethambutol and pyrazinamide. Subsequent culture confirmed positivity for TB resistant to rifampicin. Eighteen months of treatment was completed with symptom resolution. A post-treatment CT scan showed no residual lymphadenopathy.

In this case, EUS-FNA was very useful in the diagnosis of pancreatic TB, helped avoiding the need for surgery and resulted in an excellent outcome. Pancreatic/peri-pancreatic involvement of TB is rare maybe because the pancreas appears to be relatively protected

© 2012 The Authors
ANZ Journal of Surgery © 2012 Royal Australasian College of Surgeons

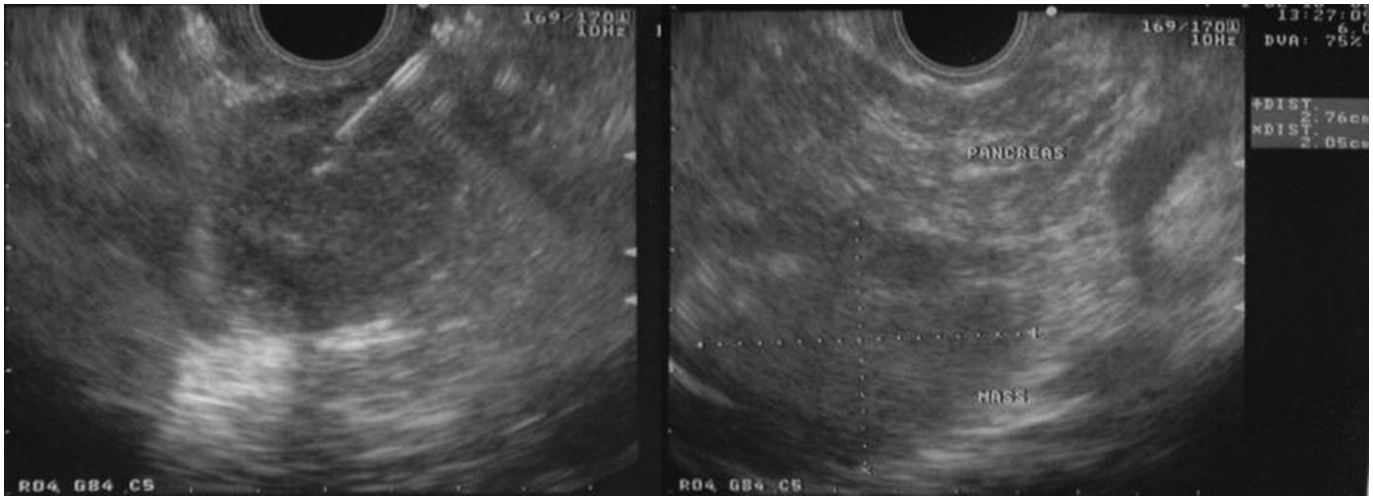

Fig. 1. EUS showing at the head of pancreas, just distal to the genu a 2.76×2.05 cm hypoechoic, ill defined mass next to the duodenum. EUS-guided FNA was performed without complication.

from *Mycobacterium tuberculosis* infection.[3] EUS-FNA has been described to be able to diagnose pancreatic/peri-pancreatic TB in 76% of patients.[4] Thus, it is crucial to make a tissue diagnosis prior to surgery to avoid unnecessary surgical resection especially in young patients or patients from endemic areas.

References

1. Lumb R, Bastian I, Carter R *et al*. Tuberculosis in Australia: bacteriologically confirmed cases and drug resistance, 2008 and 2009. *Commun. Dis. Intell.* 2011; **35**: 154–61.
2. Nair N, Wares F, Sahu S. Tuberculosis in the WHO south-east asia region. *Bull. World Health Organ*. 2010; **88**: 164.
3. Paraf A, Menager C, Texier J. Tuberculosis of the pancreas and tuberculosis of yhe lymph nodes of upper region of the abdomen. *Rev. Med. Chir. Mal. Foie* 1966; **41**: 101–26.
4. Song TJ, Lee SS, Park DH *et al*. Yield of EUS-guided FNA on the diagnosis of pancreatic/peripancreatic tuberculosis. *Gastrointest. Endosc.* 2009; **69**: 484–91.

Quetzalihuitl Arroyo Martínez,* MD
Peter DeCruz,† MBBS, FRACP
Aravinth Murugananthan,‡ MBBS, MRCP
Paul Desmond,† MBBS, FRACP
Robert Chen,† MD, FRACP
**Department of Gastroenterology, Virgen Macarena's Hospital, Seville, Spain, and †Department of Gastroenterology, St. Vincent's Hospital, and ‡Department of Gastroenterology, Western Health, Melbourne, Australia*

doi: 10.1111/j.1445-2197.2012.06006.x

Dear Editor,

Spontaneous bacterial peritonitis: a rare mimic of acute appendicitis

Spontaneous peritonitis is a potentially fatal condition often targeting young healthy patients. We report a 17-year-old sexually active female with a 12-h history of severe constant abdominal pain, initially, central and in the left flank before localizing to the right iliac fossa, associated with vomiting and diarrhoea. Examination revealed tachycardia (110 bpm), normotension (110/60 mmHg), fever (39.5°C) and generalized peritonitis. She had a normal β human chorionic gonadotropin, normal white blood cell count with lymphopaenia (0.4 × 10^9/L) and bands (3.0 × 10^9).

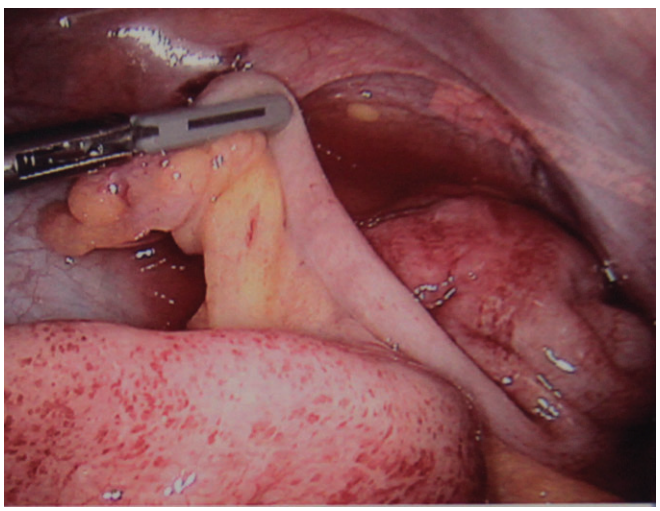

Fig. 1. Evidence of generalized peritonitis with a normal appendix.

We suspected acute appendicitis and proceeded to laparoscopy, which revealed extensive intraperitoneal purulent fluid despite a normal appendix, gall bladder, colon, uterus and ovaries (Fig. 1). There was significant inflammation of the small bowel serosa but no evidence of fat wrapping to suggest Crohn's disease. The peritoneal cavity was extensively lavaged. *Streptococcus pyogenes* was subsequently grown on culture. Further history revealed that the patient had suffered from pharyngitis 2 weeks earlier. Throat and vaginal swabs and urine polymerase chain reaction were negative for gonorrhoea and chlamydia.

© 2012 The Authors
ANZ Journal of Surgery © 2012 Royal Australasian College of Surgeons

The patient suffered septic shock day 1 post-operatively, but responded to resuscitation and intravenous benzylpenicillin for 7 days followed by 14 days of oral doxycycline, metronidazole and phenoxymethylpenicillin.

Primary peritonitis involves intraperitoneal infection without an identifiable source, a peritoneal polymorphonuclear cell count of >2.5 × 10^5/L or positive culture of an organism from intraperitoneal fluid. Spontaneous bacterial peritonitis, usually involves one organism and is most common in young women and children,[1] with *S. pneumoniae* most often implicated.[2]

There are less than 30 reported cases of primary group A – haemolytic streptococcal peritonitis – with this the only one managed surgically by laparoscopic washout. Three others were converted to laparotomy[1–3] for fear of overlooking a perforation. A review of 5522 cases of *Streptococcus pyogenes* infections found a mortality rate of 19% rising to 44% among the 13% with toxic shock-like syndrome.[4] The seriousness of *S. pyonegenes* peritonitis should be considered where there is primary peritonitis, particularly in young women and children, and necessitates aggressive monitoring and treatment.

References

1. Monneuse OTE, Gruner L, Michaillard Kaempf F, Allaouchiche B, Etienne J. Diagnosis and treatment of spontaneous group A streptococcal peritonitis. *Br. J. Surg.* 2010; **97**: 104–8.
2. Capdevila O, Pallares R, Grau I, *et al*. Pneumococcal perionitis in adult patients: a report of 64 patients with special reference to the emergence of antibiotic resistance. *Arch. Intern. Med.* 2001; **161**: 1742–8.
3. Tilanus AM, de Geus HR, Rijnders BJ, Dwarkasing RS, van der Hoven B, Bakker J. Severe group A streptococcal toxic shock syndrome presenting as primary peritonitis: a case report and brief review of the literature. *Int. J. Infect. Dis.* 2010; **14** (Suppl 3): 208–12.
4. Lamagni TL, Darenberg J, Luca-Harari B *et al*. Epidemiology of severe *Streptococcus pyogenes* disease in Europe. *J. Clin. Microbiol.* 2008; **46**: 2359–67.

Eliza R. Preece,* MBBS
Eugene Athan,† MBBS, FRACP
David A. K. Watters,* ChM FRCSEd, FRACS
David E. Gyorki,* MBBS, MD, FRACS
**Department of Surgery and †Infectious Diseases, Geelong Hospital, Geelong, Victoria, Australia*

doi: 10.1111/j.1445-2197.2012.06007.x

Dear Editor,

University of Tasmania student's foray into surgical research (Re: *ANZ J. Surg.* 2011; 81: 851–2)

The perspective from Leow *et al*.[1] raises some valid points about the importance of surgical research and promoting its interest among medical students. They also highlight the low participation rate in the Bachelor of Medical Science (BMedSci) degree among medical students. However, participation has not always been so low, Rolfe *et al*.[2] published data from the University of Newcastle over 1983–1998, finding 89 of 498 students surveyed, completed a research degree during or after medical school. Enrolment in the course also seems to vary; some universities have substantially higher participation rates than others.

As a student who has just completed the BMedSci degree at the University of Tasmania, undertaking a surgical research project, I can say the experience has been highly rewarding. The opportunity allowed me to spend the year working with a surgeon and gaining clinical experience with him, as well as completing my project. The benefits to students are clear, but there are advantages for surgical supervisors too. Depending on the project, they can gain insight into their surgical performance as their patients are analysed. Additional tuition fees are offset by scholarships and bursaries that are typically awarded in conjunction with taking on the BMedSci. A delay of 1 year in graduation is insignificant, especially in the field of medicine and surgery where lifelong learning is key.

Surgical research is an important and interesting field and there are many opportunities for students to take part in either through the BMedSci or otherwise. The results of taking part in such projects are rewarding, and students should be encouraged to participate.

References

1. Leow JJ, Haider AH, Mackay SD, Grigg MJ. Monash medical student's foray into surgical research. *ANZ J. Surg.* 2011; **81**: 851–2.
2. Rolfe IE, Ringland C, Pearson SA. Graduate entry to medical school? Testing some assumptions. *Med. Educ.* 2004; **38**: 778–86.

Cameron Louis Adams, MBBS, BMedSci (Hons)
Launceston Clinical School, University of Tasmania, Launceston, Tasmania, Australia

doi: 10.1111/j.1445-2197.2012.06008.x

Dear Editor,

Re: Cardiac surgery in the Pacific Islands

I would like to comment on this paper concerning 'Cardiac surgery in the Pacific Islands'.[1]

This excellent and frank analysis of the problems of 'off-shore' cardiac surgery reminds me of my unit's similar involvement in Vanuatu, Fiji and Mauritius 30 odd years ago. Certain crucial issues were recognized early in our experience and might be compared with those mentioned by Davis and his associates.

Evaluation of results was controlled by the same criteria that affected our triage of patients for surgery. By and large, 'productive', adult patients were preferred by referrers, regardless of clinical interest or treatment simplicity. Proximity to urban resources was fundamental in long-term (beyond hospital) care such as for clinical review, International Normalised Ratio management and general drug regimes. The latter two needs are highly undesirable. Wound healing problems require expert attention, safe Warfarin management is impossible (as it is with safety and effectiveness in 50% of all patients worldwide) and prophylactic penicillin programmes rarely provide consistent, effective coverage against rheumatic pathology.

'Primitive' patients exclude themselves unless their treatment is immediately curative. That more or less limits procedures to

© 2012 The Authors
ANZ Journal of Surgery © 2012 Royal Australasian College of Surgeons

'healthy' patients with simple congenital lesions and those with easily opened or replaced valves (disregarding costs). It is noteworthy that non-surgical techniques have a high and increasing place, particularly in correcting stenotic defects, both congenital and rheumatic, in patients of all ages. Even if patients reside in metropolitan areas where a 30-day evaluation is theoretically possible, that may be hard to achieve and regular, reliable, informed reports are difficult to maintain with confidence. Besides, the ubiquitous rheumatic factor may complicate condition and management of all patients over many years.

These remarks are not meant to be forbidding. They apply to all major ventures for any reason in any location where refined, consistent medical management cannot be ensured. The authors obviously recognize that the realities must be confronted very early in choice of patients for overseas cardiac surgery, as well as in the competence of post-operative arrangements for indefinite periods. As they observe, the relative merits of treating these patients in Australia are essential considerations, but the success of treatment will almost always be more affected by where patients live, rather than by where they are treated.

References

1. Davis PJ, Wainer Z, O'Keefe M, Nand P. Cardiac surgery in the Pacific Islands. *ANZ J. Surg.* 2011; **81**: 871–5.

John Wright, MBBS, FRACS, FACS, MSTS
1504/7 Rockwall Crescent, Potts Point, Sydney, New South Wales, Australia

doi: 10.1111/j.1445-2197.2012.06009.x

Dear Editor,

Re: Local recurrence of an oral squamous cell carcinoma confined to a free flap

We read with great interest the letter by Islam and Hoffman entitled 'Local recurrence of an oral squamous cell carcinoma (SCC) confined to a free flap', in which an intra-oral free radial forearm flap was found during follow-up to be occupied by SCC.[1] The authors postulated that this was due to local recurrence of the SCC, despite wide resection margins and absence of SCC in the native mucosa, and list a range of reasons why this may have occurred. There is one important reason left out by the authors that we feel should be considered.

Transferred flaps placed in the oral cavity have long been known to undergo 'mucosalization', with a gradual change in gross morphology that sees the exposed portion of the flap adopt the appearance of surrounding mucosa. For muscle flaps, this occurs by local in-growth of surrounding mucosa. For skin flaps, histologic changes include loss of the stratum corneum, although some authors suggest that this is not true mucosalization.[2–4] Skin flaps bathing in saliva may cause squamous epithelium to undergo metaplasia to mucosal epithelium, and we postulate that this metaplasia may precipitate a metaplasia–dysplasia–neoplasia sequence, much like that which occurs in the oesophagus in Barrett's oesophagus, in which oesophageal epithelium undergoes gastric metaplasia in the presence of gastric acid.

Other authors have also reported dysplastic changes in intra-oral skin flaps in association with candidiasis, with Woolgar *et al*. reporting 25% of biopsies associated with chronic hyperplastic candidiasis to have evidence of squamous dysplasia.[4]

New ulcerated or leukoplakic lesions associated with intra-oral skin flaps are not uncommon, and present a diagnostic challenge to surgeon and pathologist. Treatment with antifungal therapy and biopsy to exclude recurrent or new primary malignancy is warranted, and perhaps a higher index of suspicion for malignancy is warranted in the long-term follow-up of these patients.

References

1. Islam S, Hoffman GR. Local recurrence of an oral squamous cell carcinoma confined to a free flap. *ANZ J. Surg.* 2011; **81**: 948–9.
2. Khan A. Do intraoral radial forearm free flaps re-mucosalise and is candida infection relevant? *Br. J. Plast. Surg.* 2001; **54**: 299–302.
3. Woolgar J, Triantafyllou A. Histological changes in intra-oral skin flaps. *Head Neck Oncol.* 2009; **1**: 1–9.
4. Sinclair A, Johnston E, Badran DH *et al*. Histological changes in radial forearm skin flaps in the oral cavity. *Clin. Anat.* 2004; **17**: 227–32.

Warren M. Rozen,*† MBBS, BMedSc, PGDipSurgAnat, PhD
Carly Fox,*† MBBS
James Leong,*† MBBS, MS, FRACS
Simon Overstall,*† MBBS, FRACS
**Department of Plastic and Reconstructive Surgery, Dandenong Hospital, Southern Health, and †Department of Surgery, Faculty of Medicine, Monash University, Victoria, Australia*

doi: 10.1111/j.1445-2197.2012.06011.x

Dear Editor,

Carolinas Comfort Scale for mesh repair of inguinal hernia

Repair of inguinal hernias affects patients' quality-of-life (QoL) and satisfaction post-operatively.[1] The short form-36 (SF-36) questionnaire is the most popular instrument utilized to quantify the degree of pain and discomfort. However, Heniford *et al*.[2] proposed a new QoL survey, the Carolinas Comfort Scale (CCS) that specifically pertains to patients undergoing hernia repair with mesh and found that when compared with SF-36, it assessed patients' outcome and satisfaction more satisfactorily. We confirmed these findings based on a correlational analysis of these two instruments in a group of 116 patients undergoing endoscopic repair of inguinal hernia (Table 1). A very high degree of statistical significance was found between the two measures. The correlation coefficients from first to second post-operative follow-up visits all increased with the exception of the item 'coughing or deep breathing'. The variation had an absolute range of 0.04–0.37 with greatest difference seen in the item 'laying down'. These results extend Heniford's *et al*.[2] study, by demonstrating that the CCS questionnaire was still very sensitive when analysing two post-operative time points instead of one. The SF-36 concentrates on domains of QoL related to vitality, social functioning, emotional and mental health, which are more applicable to patients with chronic illnesses. For patients undergoing inguinal

© 2012 The Authors
ANZ Journal of Surgery © 2012 Royal Australasian College of Surgeons

Table 1 Short form-36 scores compared with Carolinas Comfort Scale scores at 2 and 6 weeks postoperatively

Items	2 weeks		6 weeks	
	P value	Correlation	*P* value	Correlation
Activities of daily living	<0.0001	–0.55	<0.0001	–0.68
Bending over	<0.0001	–0.53	<0.0001	–0.67
Coughing or deep breathing	<0.0001	–0.47	0.0005	–0.37
Exercising	<0.0001	–0.47	<0.0001	–0.51
Laying down	<0.0001	–0.35	<0.0001	–0.72
Walking stairs	<0.0001	–0.51	<0.0001	–0.70
Walking or standing	<0.0001	–0.48	<0.0001	–0.75
Sitting up	<0.0001	–0.48	<0.0001	–0.71

hernia repair or suffering from other benign medical conditions, a disease-specific QoL questionnaire is preferred.[3,4] Furthermore, recovery from inguinal hernia repair is normally very quick and most surgeons would review their patients twice within 2 months post surgery and uncommonly afterward. CCS measures severity of pain, sensation and movement limitations for eight different categories. Given its superior physical characteristics and statistical equivalence, we recommend that the CCS survey being the preferred QoL questionnaire used by surgeons performing this type of surgery.

References

1. Aasvang E, Kehlet H. Chronic postoperative pain: the case of inguinal herniorrhaphy. *Br. J. Anaesth.* 2005; **95**: 69–76.
2. Heniford BT, Walters AL, Lincourt AE, Novitsky YW, Hope WW, Kercher KW. Comparison of generic versus specific quality-of-life scales for mesh hernia repairs. *J. Am. Coll. Surg.* 2008; **206**: 638–44.
3. Velanovich V. Comparison of generic (SF-36) vs. disease-specific (GERD-HRQL) quality-of-life scales for gastroesophageal reflux disease. *J. Gastrointest. Surg.* 1998; **2**: 141–5.
4. Shi HY, Lee HH, Chiu CC, Chiu HC, Uen YH, Lee KT. Responsiveness and minimal clinically important differences after cholecystectomy: GIQLI versus SF-36. *J. Gastrointest. Surg.* 2008; **12**: 1275–82.

Anthony E. T. Yeo,* MBBS, PhD
Christophe R. Berney,† MD, FRACS
**Ingham Institute, Liverpool, New South Wales, and †Associate Professor, University of New South Wales, Bankstown-Lidcombe Hospital, Bankstown, Australia*

doi: 10.1111/j.1445-2197.2012.06012.x

Dear Editor,

Chondroepitrochlearis: an abnormal muscle that may affect axillary lymphadenectomy

Knowledge of the normal anatomy as well as the anatomical variations that may appear in the axilla is necessary for surgeons who perform axillary lymphadenectomy (AL). In a previous study, we reviewed the literature and examined the axilla of 107 cadavers for the presence of any abnormal muscles that a surgeon might encounter during AL. Although we found the axillary arch, the pectoralis quartus and the aplasia pectoralis major muscle, we did not find any chondroepitrochlearis muscle (CEM).[1]

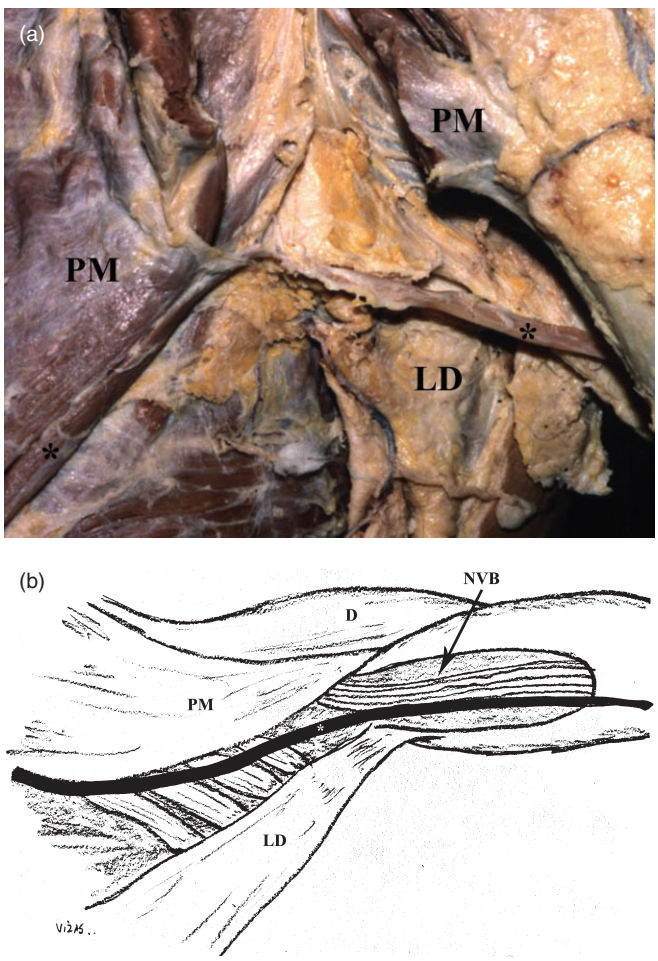

Fig. 1. The chondroepitrochlearis muscle: (a) gross appearance; (b) schematic drawing (highlighted area: *, chondroepitrochlearis muscle; D, deltoid muscle; PM, pectoralis major muscle; LD, latissimus dorsi muscle; NVB, neurovascular bundle). Reprinted with permission from Natsis *et al. Breast Cancer Res. Treat.* 2010; 120: 77–82.[1]

Since then, we dissected 12 cadavers and a CEM was found in the left axilla of an 81-year-old male cadaver. Thus, the prevalence of the CEM in our sample is 0.84% (1/119 cadavers), which is close to the 0.5% (1/200 cadavers) reported in the study by Flaherty *et al.* [2] The CEM was originated from the costal cartilages next to the lateral margin of pectoralis major muscle. At the level of the axilla it

© 2012 The Authors
ANZ Journal of Surgery © 2012 Royal Australasian College of Surgeons

followed a course deviating from the pectoralis major lateral margin, towards the medial surface of the arm. As a result the CEM crossed the anterior wall of the axilla. In the arm it became fibrous and ran in the medial bicipital groove to be inserted on the medial epicondyle (Fig. 1). These anatomical features are in accordance with the typical pattern of the CEM.[3]

According to its course, the CEM, during AL, appears as a muscular bundle that begins from the lateral margin of the pectoralis major muscle, but soon deviates from it and courses towards the medial surface of the humerus, distal to the pectoralis major muscle insertion. Thus, the CEM is located within the surgical field of AL and it may confuse the surgeon and impede the approach of the axilla content. Division of this muscle can be performed without any functional deficit for the patient.

References

1. Natsis K, Vlasis K, Totlis T *et al*. Abnormal muscles that may affect axillary lymphadenectomy: surgical anatomy. *Breast Cancer Res. Treat.* 2010; **120**: 77–82.
2. Flaherty G, O'Neill MN, Folan-Curran J. Case report: bilateral occurrence of a chondroepitrochlearis muscle. *J. Anat.* 1999; **194**(Pt 2): 313–15.
3. Loukas M, Louis RG Jr, Kwiatkowska M. Chondroepitrochlearis muscle, a case report and a suggested revision of the current nomenclature. *Surg. Radiol. Anat.* 2005; **27**: 354–6.

Konstantinos Natsis, PhD
Trifon Totlis, PhD
George Sofidis, MD
Laboratory of Anatomy, Medical School, Aristotle University of Thessaloniki, Thessaloniki, Greece

doi: 10.1111/j.1445-2197.2012.06015.x

Dear Editor,

Serratia marcescens: a historical tale forged in blood?

Recently our oncoplastic breast reconstructive service has experienced several breast implant infections caused by *Serratia marcescens*. Our investigations resulted in some interesting findings we would like the opportunity to share.

Serratia marcescens is a gram-negative rod renowned for producing a red pigment, first extracted in 1902 and named 'prodigiosin', and later described by Venetian pharmacist Bartolomeo Bizio in 1918, attributing the organism to an episode of blood-red discolouration of polenta in the city of Padua.[1] *Marcescens* was derived from the Latin 'to decay' after Bizio observed the pigment changing from light-pink material to blood-red viscous liquid.[2]

In antiquity, *Serratia spp.* had a predilection for growth on starchy foodstuffs, pigmented colonies being easily mistaken for blood.[3] In the sixth century BC, Pythagoras noted bloody concentrations on foodstuffs, and in the early nineteenth century, Ehrenberg reported nearly 100 historical references on the same phenomenon. The first recorded reliable account was in 332 BC at the siege of Tyre in Phoenica. The vast Macedonian armies of Alexander the Great took inspiration from an omen predicting the destruction of Tyre from blood they had seen trickling out of the soldiers' bread. Alexander interpreted this omen as a sign of impending success and rallied his previously dispirited troops to victory.[4]

The ability of *Serratia spp*. to grow on bread coupled with the red pigmentation resulted in it being attributed to the explanation of medieval accounts of the 'miraculous' appearance of blood on the Eucharist (Holy Communion). This led to the institution of the Feast of Corpus Christi in 1264 by Pope Urban the IV, following a celebration in 1263 of a Mass at Bolsena in which a German priest Peter of Prague, doubting transubstantiation in which the bread and wine were used for the body and blood of Christ, broke open bread and was met with a blood red appearance.[3] This event was subsequently celebrated in a painting on the walls of the Vatican by painter Raphael depicting the Miracle at Bolsena (see Figure 1). The starchy sacrament incubated in the damp medieval church environment provided an excellent medium for the growth of *Serratia marcescens* and as the Eucharistic bread symbolized the conversion into the body of Christ such an appearance of blood represented a dramatic testament to this dogma.

We find it fascinating that such an organism could have had such a substantial and profound impact in history, the effects of which still echo in contemporary religious culture.

References

1. Merlino CD. Bartolomeo Bizo's letter to the most eminent priest, Angelo Bellani, concerning the phenomenon of the red colored polenta. *J. Bacteriol.* 1924; **9**: 527–43.
2. Yu VL. *Serratia* infection in the surgical patient. *Infect. Surgery* 1984; **3**: 127–34.
3. Gaughran ERL. From superstition to science: the history of a bacterium. *Trans. N Y Acad. Sci.* 1969; **31**: 3–24.
4. Yu VL. *Serratia marcescens*: historical perspective and clinical review. *N. Engl. J. Med.* 1979; **300**: 887–93.

Vladimir Saravolac,* MBChB, BSc (Hons)
Iain Whitaker,† MBBChir, PhD, FRCS
Damien Grinsell,† MBBS, FRCAS
Mark Ashton,† MBBS, MD, FRCS (Plast)
**Department of Surgery and Wound Healing, Cardiff University, School of Medicine, Upper Ground Floor, Heath Park Cardiff, Cardiff, United Kingdom, and †Royal Melbourne Hospital, Plastic Surgery Melbourne, Victoria, Australia*

doi: 10.1111/j.1445-2197.2012.06016.x

Dear Editor,

Operating theatre: the unacknowledged classroom of the modern medical degree

There has been much talk in recent years about the quality of modern medical education. In Australia, student numbers have swelled to meet the demands of a growing and ageing population, with the result a more than doubling of medical graduates over the past 10 years.[1] This exponential growth in intake, in the context of only a moderate expansion of training places, has resulted in over

© 2012 The Authors
ANZ Journal of Surgery © 2012 Royal Australasian College of Surgeons

Fig. 1. Raphael's *The Miracle at Bolsena* (1512–1514) in the Vatican Museum's Stanza di Eliodoro. Inset, close-up of painting showing 'blood' dripping from Eucharist.

stretching of resources and an undeclared decline in both the quantity and quality of clinical teaching available to today's students. It is a frustrating situation for clinicians and trainee doctors alike, the elder of whom struggle to find appropriate teaching opportunities for the increased number of students, and the younger who feel both alarmed and discouraged by the lack of clinical exposure they have had by graduation. One of the most striking deficits of the current system is the lack of one on one time with consultants. When up to eight students attend a bedside tutorial given by a single doctor, it greatly limits the opportunity for the 'question and answer' style of learning that is widely regarded in medical education.[2] Ward rounds, which are traditionally considered the cornerstone of clinical instruction, are often conducted in haste with teaching a mere afterthought.[3] Anecdotally, this swift review of patients has led to mild resentment among medical students, many of whom complain of the futility of their forced attendance at these events, participating only as a means of obtaining a passing grade in that particular rotation.

With so many of the customary avenues for learning having been scuttled, where should the medical student turn for meaningful teaching? The answer is the operating theatre. Assisting in surgery provides a chance to spend intensive time with a consultant, discussing the patient, the disease and the reasoning upon which their management is based. The Socratic method of teaching still thrives in this environment, where you can simultaneously retract while being challenged for your knowledge. In a time when teaching of the basic sciences has been condensed to a year and sometimes less, reviewing anatomy with an experienced instructor, who simultaneously identifies the structure while demonstrating its function, is invaluable.

I am currently enrolled in the fifth year of my medical studies; however, during the last 2 years on the wards, I have placed only two cannulas and inserted one catheter. In the same time, I have assisted in the removal of at least 25 breasts, 10 gallbladders, 2 appendices and roughly 15 skin cancers. I have helped dress wounds, learnt about fluid status, regeneration and healing. I now understand the principles of analgesia, the importance of multidisciplinary teams in ensuring the best possible outcomes for patients, and have come to appreciate anatomy in a way that is clinically relevant. For those medical students who lament the loss of the old system of learning, I say seek new opportunities. They exist; you just need to find a friendly surgeon.

References

1. Medical Deans Australia and New Zealand Inc. *Medical Student Statistics – Snapshots.* First Edition [Internet]. Sydney: New South Wales, [updated 2010; Cited 31 Aug 2011.] Available from URL: http://www.medicaldeans.org.au/statistics/snapshots
2. Oh RC. The Socratic method in medicine – the labor of delivering medical truths. *Fam. Med.* 2005; **37**: 537–9.
3. Melo PH, Hannois FG, Rodrigues FA, Natal FJ. Active learning on the ward: outcomes from a comparative trial with traditional methods. *Med. Educ.* 2011; **45**: 273–9.

Kendall Sharpe, BSc (Hons I)
University of Western Australia, Perth, Western Australia, Australia

doi: 10.1111/j.1445-2197.2012.06017.x

© 2012 The Authors
ANZ Journal of Surgery © 2012 Royal Australasian College of Surgeons